



Alberta Thiadens



cone photoreceptor disorders

This work was published in:

Thiadens AA, den Hollander AI, Roosing S, Nabuurs SB, Zekveld-Vroon RC, Collin RW, De Baere E, Koenekoop RK, van Schooneveld MJ, Strom TM, van Lith-Verhoeven JJ, Lotery AJ, van Moll-Ramirez N, Leroy BP, van den Born LI, Hoyng CB, Cremers FP, Klaver CC. Homozygosity mapping reveals PDE6C mutations in patients with early-onset cone photoreceptor disorders. *Am J Hum Genet.* 2009 Aug;85(2):240-7.

UNDERSTANDING THE GENETICS OF CONE DISORDERS

Cone disorders are a group of inherited eye diseases which affect the cone photoreceptors of the retina and may lead to legal blindness before middle age. The disorder can be clinically subdivided in achromatopsia (ACHM), cone dystrophy (CD), and cone-rod dystrophy (CRD). ACHM is a congenital disorder characterized by low visual acuity, photophobia, severe color vision defects, and no recordable or only residual cone function on the electroretinogram (ERG). In CD the deterioration of visual acuity starts later in life; around the first or second decade. In CRD initially the cones, but at a later stage also the rod photoreceptors are affected. The genetic background of ACHM has been elucidated to a great extent, while the causative genes of CD and CRD are largely unknown.

Our aim was to identify causative genes for autosomal recessive (ar) cone disorders by genome-wide homozygosity mapping in consanguineous and nonconsanguineous patients. We investigated 75 ACHM, 97 arCD, and 20 early-onset arCD probands, and excluded the involvement of known genes. Subsequently, we performed high-resolution

SNP analysis, and identified large homozygous regions spanning the PDE6C gene in one sibpair with early-onset arCD, and in one sibpair with ACHM. The PDE6C gene encodes the cone α -subunit of cGMP phosphodiesterase, which converts cGMP to 5' GMP, and plays an essential role in cone phototransduction. Sequence analysis of the coding region of PDE6C revealed homozygous missense mutations in both families. The mutation found homozygously in sibs with early-onset CD (M1) was located just upstream of the GAF-A domain (Figure 1). The visual acuity and cone ERG progressively declined in early teens. Patients from another family with incomplete ACHM carried a homozygous missense mutation (M4) in the GAF-B domain, which presumably affects the interaction with cGMP. The cone ERG responses were significantly reduced but measurable both in childhood as at recent examination. Subsequent sequence analysis of 104 probands with arCD and 10 probands with ACHM revealed compound heterozygous PDE6C mutations (M2/M6 and M3/M5) in patients from two other families with ACHM (Figure 1). Typical fundus photo-

graphs of an CD and ACHM patient are shown in Figure 2.

To visualize the cone photoreceptor layer in the retina, we performed Optical Coherence Tomography (OCT) in all adult patients. All patients showed absence of cones in the macula (Figure 2), however, the area of missing cone photoreceptors was significantly smaller in the cone dystrophy patient versus the achromatopsia patient. We hypothesize that the missense variants (M1) in the cone dystrophy patient, which is located outside functionally important domains, may have a less severe effect on the function of PDE6C.

In conclusion, PDE6C mutations result in a severe early-onset cone disorder. We show that ACHM and early-onset CD form a continuous spectrum of similar etiology. The observed variability in phenotypes may be due to differences in the functional effects of PDE6C mutations. Our findings will help improve diagnosis and counseling of patients and their families, and brings us a step closer to solving the etiology of cone photoreceptor disorders.

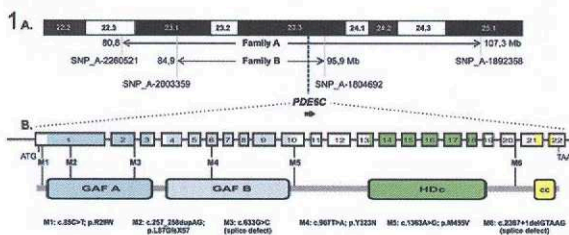


Figure 1: Molecular genetic characterization of the PDE6C gene in families with autosomal recessive cone photoreceptor disorders. A. The 10q22-q25 region and the homozygous regions identified in patients of two families. B. Protein and genomic structure of PDE6C, as well as six mutations (M1-M6) that were found to segregate in four families with cone dystrophy or achromatopsia.

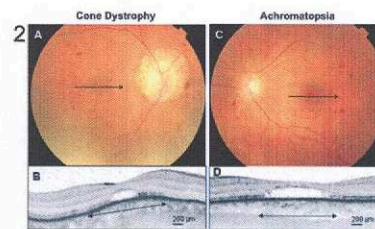


Figure 2: Retinal phenotypes of cone dystrophy and achromatopsia in two families. A. Fundus picture of cone dystrophy patient, showing myopic changes around the optic nerve and mild pigmentary changes in the macula. The arrow denotes the position of the OCT image in B. B. OCT of the cone dystrophy patient reveals a serous detachment of the photoreceptor layer in the central fovea. The outer and inner segments of the photoreceptors are absent. The length of the lesion is ~500 μ m. C. Fundus picture of achromatopsia patient, showing mild pigmentary changes in the macula. The arrow denotes the position of the OCT image in D. D. OCT of achromatopsia patient which shows a large area of ~1300 μ m with absent cone photoreceptors.