



hers
tumor
centrum

PRIMARY INTRACRANIAL GERM-CELL TUMOURS IN ADULTS

Evaluation and treatment protocol

**Dutch Society for Neuro-Oncology
(Landelijke Werkgroep Neuro-Oncologie, LWNO)**

April 27, 2012

Comprehensive Cancer Centre the Netherlands
(Integraal Kankercentrum Nederland)
Utrecht

1 Working group

Chairman

- J.E.C. Bromberg, MD, PhD, neurologist, Erasmus Medical Centre, Rotterdam, j.bromberg@erasmusmc.nl

Working group members

- B.G. Baumert, MD, PhD, radiation oncologist, Maastricht University Medical Centre, Maastricht, brigitta.baumert@maastro.nl
- J.M.M. Gijtenbeek, MD, PhD, neurologist, Radboud University Nijmegen Medical Centre, Nijmegen, j.gijtenbeek@neuro.umcn.nl
- E. Kurt, MD, neurosurgeon, Radboud University Nijmegen Medical Centre, Nijmegen, E.Kurt@nch.umcn.nl
- A.Y.N. Schouten-van Meeteren, MD, PhD, pediatric oncologist, Academic Medical Centre Amsterdam, a.y.n.schouten@amc.uva.nl
- F. de Vos, MD, PhD, medical oncologist, University Medical Centre Utrecht, Utrecht, f.devos@umcutrecht.nl
- P. Wesseling, MD, PhD, neuropathologist, Radboud University Nijmegen Medical Centre, Nijmegen and VU University Medical Center Amsterdam p.wesseling@pathol.umcn.nl
- A.M. Westermann, MD, PhD, medical oncologist, Academic Medical Centre Amsterdam, a.m.westermann@amc.uva.nl

Secretary and contact person

- M.L. van de Kar-van der Meulen, Comprehensive Cancer Centre the Netherlands, Utrecht, vandekar@planet.nl

Advisor (cancer registry)

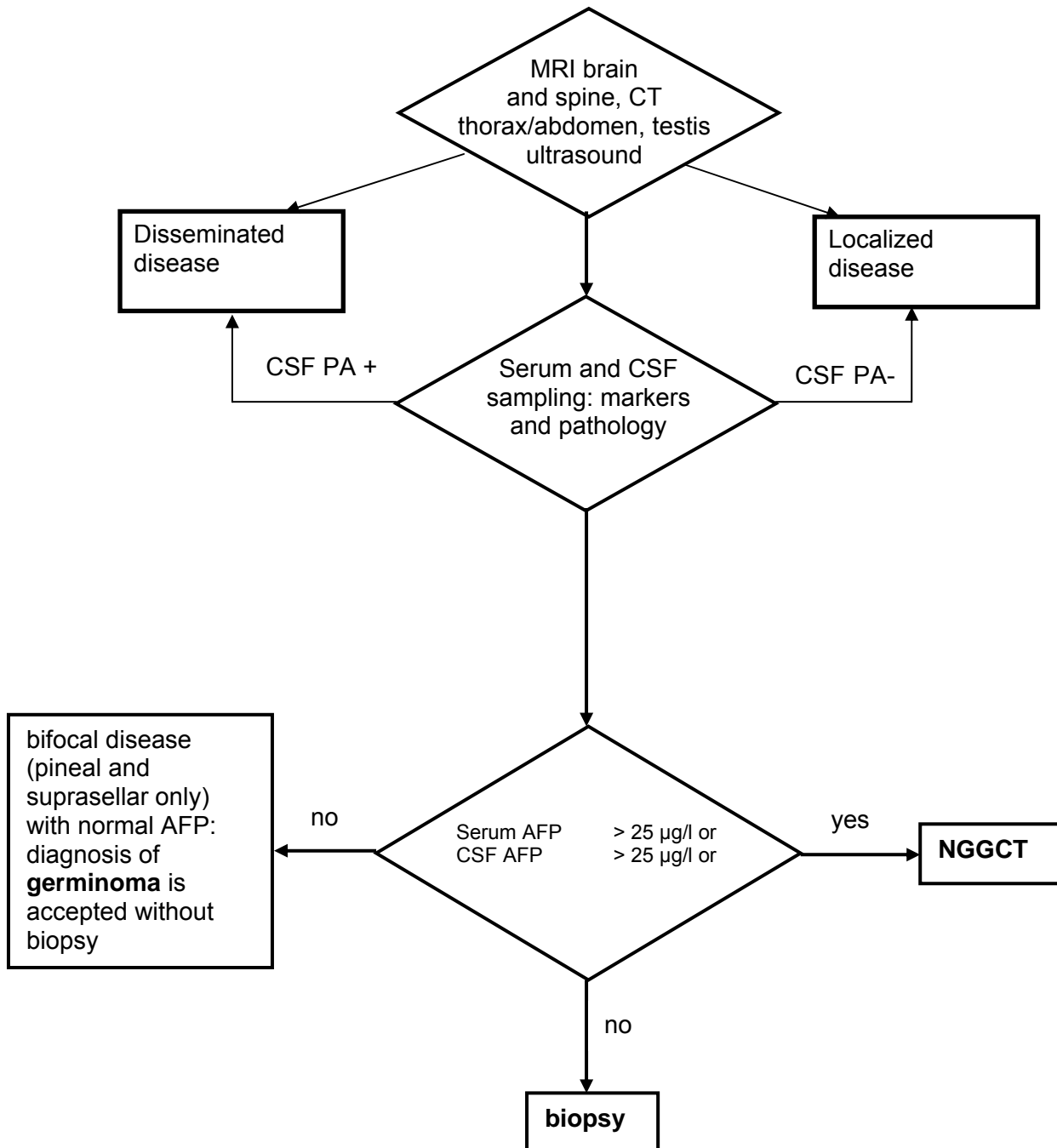
- V.K.Y. Ho, MSc, epidemiologist, Netherlands Cancer Registry, Comprehensive Cancer Centre the Netherlands, Utrecht, vho@ikmn.nl

2 Table of contents

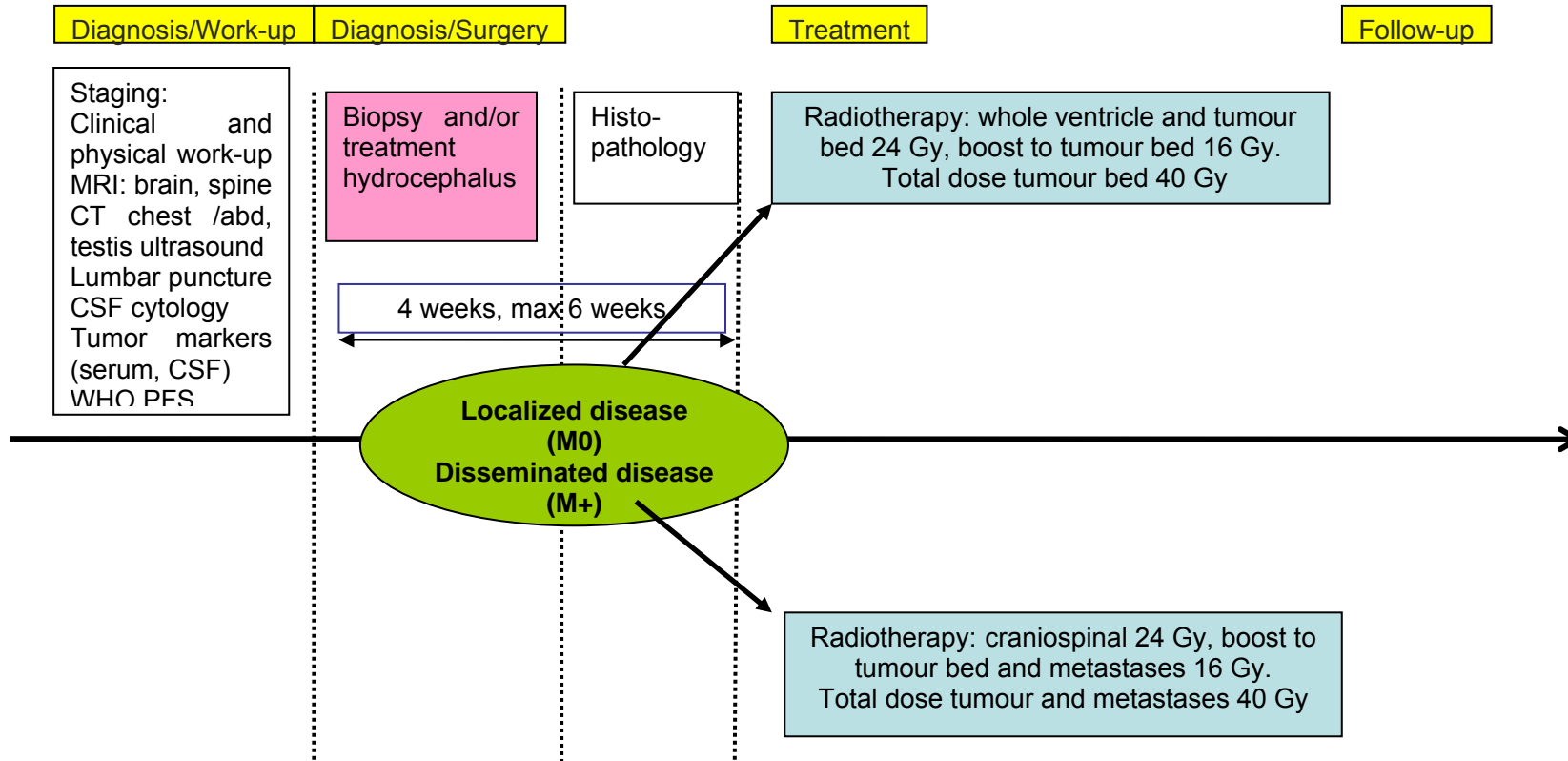
1	Working group.....	2
2	Table of contents.....	3
3	Summary, flowcharts and time schedule	4
4	Background	5
4.1	Introduction	5
4.2	Pathology and molecular genetics ^{8,9}	5
4.3	Clinical presentation and diagnostic investigations	7
4.4	Neurosurgery	8
4.5	Radiotherapy	9
4.6	Chemotherapy	10
4.7	Follow-up	10
4.8	Prognosis.....	10
5	Objectives	11
6	Eligibility and registration	12
6.1	Inclusion criteria.....	12
6.2	Registration.....	12
7	Treatment.....	13
7.1	Diagnostic work-up	13
7.2	Neurosurgery	13
7.3	Radiation therapy.....	14
7.4	Chemotherapy, schedules and management	17
7.5	Follow-up	21
8	Table of evaluations	22
9	References.....	24
	Appendix A: Checklist protocollaire behandeling met PEI bij intracerebrale non-germinomen	27
	Appendix B: ZUBROD-ECOG-WHO Performance Status	30
	Appendix C: RTOG neurologic function status.....	31
	Appendix D: MR imaging – minimal requirements	32

3 Summary, flowcharts and time schedule

Flowchart: Diagnosis and extent of disease

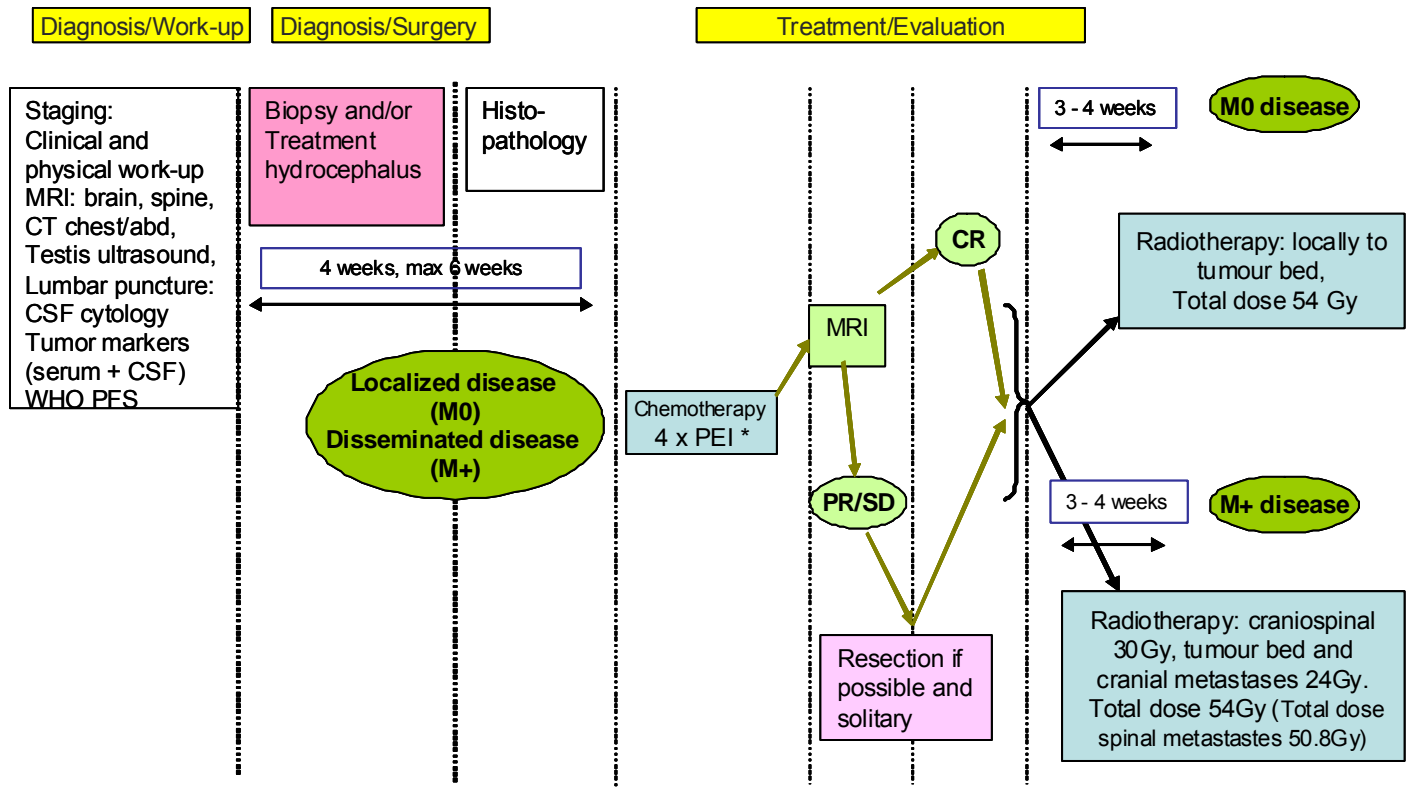


Flow-chart: adult germinoma



February 2012

Flow-chart: adult non-germinoma



*Cisplatin, Etoposide, Ifosfamide

February 2012

4 Background

4.1 Introduction

Intracranial germ cell tumours (GCTs) are rare tumours of childhood and adolescence with an incidence of 0,1–0,2 / 100 000 per year in children up to the age of 15.¹ In the past 10 years only 3–4 patients aged 18 or over were diagnosed annually with an intracranial GCT in The Netherlands. GCTs are heterogenous with respect to their histology, biological profile and response to treatment and may or may not secrete tumour markers (AFP and/or Beta-HCG) into serum and/or CSF. Two main groups are distinguished: the germinomas and the non-germinomatous germ-cell tumours (NGGCT). Germinoma is the most common subtype accounting for approximately two thirds of the germ-cell tumours and is histologically identical to testicular seminoma and dysgerminoma of the ovary.^{2;3} The NGGCTs are histologically differentiated into embryonal cell carcinoma, yolk sac tumour, choriocarcinoma and mature or immature teratoma. Mixed tumours of various subtypes account for 30% of CNS germ-cell tumours.⁴ Prognosis is highly variable and depends on the histology and dissemination. Localised germinomas are exquisitely radiosensitive and can be cured with radiotherapy alone, although metastases can develop occasionally. Mature teratomas can be cured if complete resection can be achieved. The other NGGCTs are associated with the worst prognosis with 5-year survival rates in the range of 9–49% even with aggressive treatment.^{2;5}

Germ-cell tumours most frequently develop at or around puberty or and in the second or third decade of life. Given the rarity of this disease in adults literature for this patient population is scarce and prospective studies have not been performed. Prospective co-operative studies have, however, been performed in children and may to some extent be extrapolated to adults.

Because of the rarity of the disease, prospective studies are difficult to perform. Therefore a protocol has been set up for diagnosis and treatment based on the available literature in order to achieve uniform treatment of adult patients with primary intracranial germ-cell tumours within The Netherlands and allow prospective toxicity and efficacy data to be collected for a larger number of patients than is feasible in a single centre. The current guideline is aimed at patients over the age of 18 and based on an on-going observational protocol by the International Society for Paediatric Oncology (SIOP) with adaptations for expected differences between children and adults. In patients with intracranial germinoma, trials combining chemotherapeutic schemes with radiotherapy have shown poorer relapse free survival than after radiotherapy alone.^{6;7} Although in developing children toxicity of cranial irradiation has incited studies, including the current SIOP protocol, further investigating chemoradiation, in adults the toxicity of radiotherapy is less and does not seem to warrant the risk of inferior tumour control.

Given the limited experience with this disease referral to a neuro-oncological centre is advised. Patients up to and including 18 years of age should be included in the international SIOP protocol whenever possible.

4.2 Pathology and molecular genetics^{8;9}

The accurate histological (sub)classification of germ-cell tumours of the CNS is critical for treatment planning and prognosis. Two main groups are distinguished: the germinomas and the non-germinomatous germ cell tumours (NGGCT). While germinoma and teratoma are frequently encountered as pure tumor types, other intracranial germ cell neoplasms are often of mixed histologic composition.

World Health Organization classification of intracranial germ cell tumours^{8;9}

Germinomas	65%
Non-germinomatous germ cell tumors	35%
Embryonal carcinoma	
Yolk sac tumor	
Choriocarcinoma	
Teratoma	
Benign teratomas	
Immature	
Mature	
Teratoma with malignant transformation	
Mixed germ cell tumors	

Germ-cell tumours of the CNS have been assumed to originate from primordial germ cells that either migrate in aberrant fashion, or home to the embryonic CNS rather than the developing genital ridges. This hypothesis is, however, controversial. An alternative explanation for the occurrence of these intracranial germ cell tumours is derivation of neural stem cells that acquire pluripotent capacity. The exact molecular pathways leading to oncogenesis of germ cell tumours of the CNS are not known. Germ cell tumours may show pure germ cell differentiation (germinoma; synonym for lesion with same histology in testis 'seminoma' and in ovary 'dysgerminoma') or somatic differentiation. The existence of a common cell of origin may help to explain the histological heterogeneity within mixed malignant germ cell tumours.

Subtypes of non-germinomatous germ cell tumours can be distinguished based on radiological, pathological (incl. immunohistochemical) features and levels of particular markers in blood and/or cerebrospinal fluid (CSF).

Most germ-cell tumours show immunohistochemical staining for placenta-like alkaline phosphatase (PLAP). Germinomas usually express c-Kit (CD117), the receptor for stem cell factor, an important mitogen for normal germ cells. Embryonal carcinomas are frequently CD30 positive. Teratomas typically show components of all three germ layers which may be mature and/or immature in aspect. Examples of mature components are epidermis with skin appendages (incl. hair follicles/hair), teeth, cartilage, bone, glial and thyroid tissue. Immature neural tissue with neurotubular structures is frequently seen in immature teratomas.

4.2.1 Molecular biology

Germ-cell tumours of the CNS (beyond early childhood), show complex chromosomal anomalies including gains of chromosomes 12p, 8q, 1p and X, as well as losses of 11q, 13 and 18q. Whether 12p gain, isochromosome 12p formation, and X duplication, especially characteristic of testicular and mediastinal germ-cell tumours, occur at comparably high frequency in CNS tumours is debated (Louis, WHO). Klinefelter syndrome (47, XXY) is associated with an increased risk of intracranial germ-cell tumours. Up till now, the contribution of molecular analysis in the diagnosis and further characterization of germ-cell tumours is limited.

4.2.2 Biological characteristics

GCTs may secrete specific tumour markers including alpha-foetoprotein (AFP) and human chorionic gonadotropin (β -HCG). AFP is normally synthesized by yolk sac endoderm; high levels typically signal the presence of yolk sac tumour elements. Marked elevations of β -

HCG suggest that components of choriocarcinoma are present, since β -HCG is normally secreted by syncytiotrophoblastic cells. See the section clinical presentation and diagnostic investigations for the implications of these markers for diagnosis and treatment.

4.3 Clinical presentation and diagnostic investigations

4.3.1 Clinical presentation

The symptoms and signs at presentation of GCTs and their appearance are dependent on the site of involvement and on histological tumour types. Typical locations are pineal region (51%) and supra-sellar (30%) with at least 15% having tumours at multiple sites.⁴ Especially germinomas tend to bifocal location in pineal and suprasellar regions without metastasizing elsewhere in about 25-30% of cases.³ The vast majority (95%) of patients with tumours in the pineal region presents with symptoms and signs of intracranial hypertension (headache and papilloedema), including Parinaud's sign in 73% and diplopia in 24% as a result of obstruction of the aqueduct, invasion of the tectal plate, and hydrocephalus. In patients with suprasellar tumours the majority presents with hypothalamo-hypophysial endocrine disturbances such as diabetes insipidus (86%) or visual disturbances caused by invasion of the optic chiasm (85%). Females older than 12 years frequently manifest primary or secondary amenorrhea (93%).⁴ Tumours in other locations occur much less frequently but tend to cause symptoms and signs compatible with the location. Duration of symptoms before diagnosis is related to velocity of tumour growth, being longer in germinoma (especially of the suprasellar site) in comparison to malignant NGGCTs. Median time from first symptom to diagnosis in suprasellar germinoma is reported to range from 3 to 36 months.

4.3.2 Imaging

MRI is the best imaging modality although CT can contribute information on tumour cellular density and calcification. MRI appearances in typical locations (suprasellar, pineal, bifocal), in conjunction with clinical signs, are strongly predictive of the presence of an intracranial GCT. Germ-cell tumours other than teratomas usually appear as a solid mass, similar of intensity to the grey matter showing prominent enhancement after administration of contrast. Of all tumours in the pineal region, GCTs are the most common, accounting for 31-85% of pineal region tumours.⁵

The differential diagnosis in the pineal region includes pineal parenchymal tumours such as the pineocytoma, pineoblastoma and pineal parenchymal tumour of intermediate determination, gliomas, meningioma, ependymoma or metastasis. In the suprasellar sites the main differential diagnosis is Langerhans Cell Histiocytosis and sarcoidosis for small lesions, low-grade glioma or craniopharyngeoma for larger lesions. The most common characteristic of GCTs is calcification of the pineal gland. In addition germinoma may show a calcified pineal gland with symmetric 'butterfly' wings of tumour and cases involving both the suprasellar region and pineal gland without dissemination are most likely to be germinomas. Germinomas located in the basal ganglia frequently do not enhance with gadolinium and their mass effect may be faint or absent.² Teratomas frequently have heterogeneous signal characteristics due to fat, cysts and calcification, choriocarcinoma may have intense contrast enhancement and a high propensity for intratumoral haemorrhage and pineocytoma show a slightly increased signal intensity on FLAIR and T2/weighted images and are likely to have a cystic component.⁵ However, to obtain a definitive diagnosis, biopsy must be performed in all cases unless pathognomonic serum or CSF elevation of tumour markers can be demonstrated.²

4.3.3 Tumour Markers

GCTs may secrete specific tumour markers: α -fetoprotein (AFP) and β -HCG, which are not produced by any other primary intracranial tumour. One or both of these markers are elevated at diagnosis in the majority of patients with malignant NGGCTs (80% in the serum,

>60% in CSF),¹⁰ and their presence, in conjunction with consistent MRI appearances, is sufficient for the diagnosis without the need for biopsy.

Yolk sac tumours typically secrete alpha-fetoprotein (AFP) and choriocarcinomas human chorionic gonadotropin (HCG).¹¹ Pure embryonal carcinoma and teratomas are usually not associated with specific tumour markers in blood or CSF.

Histology	Clinical behaviour	Tumour markers		Sensitivity to	
		AFP	total HCG	Chemo	Irradiation
Germinoma	Malignant	-	(+)	+++	+++
Embryonal CA	malignant	-	-	+++	++
Yolk sac tumour	malignant	+	-	+++	++
Choriocarcinoma	malignant	-	+++	+++	++
Teratoma	benign (potentially malignant)	-	-	-/?	+/-

AFP is a glycoprotein with a half-life of 5 days. The cut-off value for germ-cell tumours (serum) is 25 ng/ml (=25 µg/l). Total HCG is produced by the placenta or similar structures. Half-life is 16 hours, normal laboratory value is <5 IU/l.

In germinomas AFP is **never** elevated. However, germinoma may be associated with mild elevation of total HCG (generally less than 50 IU/l in serum and CSF) indicating the presence of syncytiotrophoblastic cells. In this protocol biopsy will be performed in patients with normal AFP and elevated β-HCG.

4.4 Neurosurgery

4.4.1 Background

Because radiotherapy and chemotherapy are the backbone of treatment for patients with germinomas as well as non-germinomatous germ cell tumours, the indication for extensive neurosurgical procedures is limited. In general, the role of neurosurgery in patients with a suspected germ cell tumour consists of a biopsy in order to confirm the diagnosis. Even biopsy is not indicated when the patient with a suspected germ-cell tumour shows characteristic elevation of tumour markers in blood and/or CSF or typical bifocal pineal and suprasellar disease on cranial MRI without further dissemination. The value of extensive surgical resections at diagnosis is unproven¹² and may even lead to neurological and endocrinological deterioration.¹³

4.4.2 Tumour biopsy and tissue sampling

A disadvantage of biopsy is the risk of sample error, which can lead to an inaccurate tissue diagnosis, especially in those patients who do have a mixed germ cell tumour (tumour contains both germinoma and non-germinoma components). Precise data on the risk of sample error are lacking, but the risk is considered to be low.¹⁴ Biopsy can be performed either with neuronavigation guided techniques, stereotactic procedures as well as via an endoscopic approach.¹⁵

4.4.3 Treatment of hydrocephalus

In cases of hydrocephalus CSF shunting may be necessary. Option is to place a ventriculoperitoneal shunt, however tumour spread bringing tumour cells into the abdomen and pelvis has been documented.¹⁶ If technically possible, an endoscopic third ventriculostomy is preferable to lower the risk of dissemination, although even with this technique it has been described.¹⁷ An additional benefit of neuroendoscopy is the ability to simultaneously perform tumour biopsy.¹⁵ Collection of CSF (to assess tumour markers and

cytology) is strongly recommended and easy to perform in a neuroendoscopic procedure or ventriculoperitoneal shunt placement. CSF must be collected before biopsy or surgery of the tumour.

4.4.4 Indications for extensive procedures

- 1) Patients who suffer acute obstructive visual deterioration from a suprasellar mass
- 2) Proven mature teratomas (after a previous biopsy) with normal tumour markers. In these patients gross total resection is recommended since surgery is curative and no further interventions are required.
- 3) Patients with a single residual mass after chemotherapy within the non germinoma group. The tumour recurrence rate is much higher and the outcome shows a poorer prognosis when compared with patients who do not have a residue. Non-germinomatous GCT often are relatively resistant to conventional chemotherapy and radiotherapy; total resection by second look operation improves disease control.² This is in line with treatment of extracranial germ-cell tumours. Small residual masses within the germinoma group that have responded to radiotherapy should not be resected but a watch-and-wait strategy should be the policy (SIOP CNS GCT 96 trial).
- 4) Patients with localized disease who do not show any response to chemoradiotherapy. The optimum timing of surgery is after the end of chemotherapy, but it may also be considered following radiotherapy.

4.5 Radiotherapy

4.5.1 Germinoma

In the literature mainly retrospective research for germinoma in adults is reported and most publications report on a combination of children and young adults. In general, radiotherapy alone can cure in excess of 90% of patients with germinomas with either craniospinal irradiation (CSI)¹⁸⁻²³ or peri-ventricular irradiation.^{19;24-26} The formerly used irradiation of the entire craniospinal axis has been abandoned for reasons of significant endocrine and neurocognitive toxicities and based on several reports of equivalent control rates with the use of limited irradiation to the intracranial ventricular system.^{21;22;24;27-31}

For germinoma, it is important that radiation fields cover the whole peri-ventricular area and not only the local tumour bed in order to achieve same local control as with CSI. Only one publication reports solely on adult patients with a median age of 24 years. After a median follow-up of about 11 months and low-dose craniospinal radiotherapy of 25 Gy with a boost dose to the tumour to a total dose of 40 Gy they have observed no relapses and no deaths.³² Earlier reports concluded that germinoma occurring in the basal ganglia would require whole brain irradiation, as they invade deep brain tissue and relapses can occur outside of the peri-ventricular area.^{33;34} However, newer published evidence (in children) supports the use of local ventricular irradiation (VFI) for these patients as well as for those with bifocal tumours in case chemotherapy was added.^{35;36} For bifocal tumours VFI is sufficient if there is no other evidence of metastatic disease or positive CSF.³⁷

4.5.2 Non-germinoma

For non-germinoma, radiation therapy alone is rarely curative but an essential treatment modality. Most tumours relapse within 18 months.³⁸ Chemotherapy alone is also not sufficient as high relapse rates of 50% have been reported.^{39;40} The combination of radiotherapy with platinum based chemotherapy plays a key role in non-germinomatous malignant germ cell tumours. Published evidence reports on the important role of radiotherapy in these malignant intracranial tumours. A dose higher than 50 Gy should be given to the local tumour bed (SIOP CNS GCT 96).^{6;41;42} For non-metastasised tumours focal irradiation is sufficient when combined with platinum-based chemotherapy.

4.6 Chemotherapy

4.6.1 Germinoma

Large retrospective series and prospective trials have shown that irradiation alone is a safe therapy yielding high cure rates. In view of the excellent results of radiotherapy only, chemotherapy is not indicated for adults with intracranial germinoma, regardless of the disease stage.²¹ The estimated relapse free survival rate was 91% with a median follow-up time of 59.5 months (range 3–180 months). Trials combining chemotherapeutic schemes with radiotherapy did not improve the relapse free survival.^{6,7} In contrast to the pediatric population, adult tolerance of radiotherapy is acceptable whereas chemotherapy toxicity is greater. The incentive to decrease radiotherapy dose and replace it with chemotherapy is therefore largely absent.

4.6.2 Non-germinomatous germ-cell tumours

Non-germinomatous germ-cell tumours display a high responsiveness to chemotherapeutic agents, although chemotherapy alone is insufficient to achieve cure, as it is associated with a 50% relapse rate in 26 patients in the Memorial Sloan Kettering Cancer Centre Group cohort.^{39,40} In the SIOP CNS GCT 96 trial, 189 patients with intracranial non-germinoma were treated with four cycles of cisplatin, etoposide and ifosfamide (PEI). In non-metastatic disease, focal irradiation with 54 Gy was then administered, while patients with metastatic disease were treated with craniospinal irradiation with 30 Gy and a boost of 24 Gy to all sites of visible tumour on MRI.⁴³ The study resulted in 10 years event free survival of 70% and in 10 years overall survival of 67% with a median follow-up of 40 months. The combination of radiotherapy with platinum-based chemotherapy has a key role in achieving optimal outcome and has now become the treatment standard in this group of tumours. It has not been proven that high-dose chemotherapy plus autologous haematopoietic stem cell support given as first-line therapy increases survival. However, in a review article, a 10% improvement in survival with early intensification of salvage treatment using high-dose chemotherapy was mentioned.⁴⁴ Therefore, high-dose chemotherapy should not be used outside of a prospective clinical trial.

Salvage therapies for relapsed GCTs include surgery, local or whole neuroaxis irradiation, and myeloablative chemotherapy with autologous blood stem cell rescue. There is no preferred treatment scheme, although good efficacy has been reported with myeloablative chemotherapy with stem cell rescue.⁴⁵

4.7 Follow-up

Most cases of relapsed CNS germ-cell tumours occur within 5 years and at the primary tumour site although in up to 30% of cases distant metastases occur.^{2,46} Median time to relapse was 12 months (range 7-120), though in germinoma median time to first recurrence has been reported to be 50 months after initial treatment.^{2,45,47} Therefore surveillance should be most intensive in the first year after treatment and should continue at least 5 years, preferably 10 years.

4.8 Prognosis

Prognosis is determined by pathology of the tumour, extent of disease and presence or absence of elevated tumour markers. Overall survival in patients with pure germinoma at 5 years is >90% after radiotherapy only, 5-year survival in mixed germinomatous and non-germinomatous GCT is around 70%, in NGGCT it is less than 50%.² Since elevated AFP is a marker of the NGGCTs this coincides with a poorer prognosis. In patients with pure germinoma, elevated serum β -HCG does not seem to influence prognosis although a small study in 12 patients found a poorer prognosis in patients with elevated β -HCG in CSF.^{10,11,48} In patients with NGGCTs survival was worse in patients with elevated β -HCG after chemotherapy-based treatment with a HR of death of 1.9 for patients with raised markers.⁴⁸

5 Objectives

The objectives of the current protocol are to:

- 1) treat all adult patients with a primary intracranial germ-cell tumour in The Netherlands in a uniform manner through a comprehensive protocol;
- 2) document the feasibility of this treatment protocol by recording side-effects and actually administered treatment in a standardized fashion;
- 3) document the outcome of adult primary intracranial germ-cell tumours in EFS and OS after treatment in this standardized treatment protocol;

To this end, all patients will be prospectively registered in a central database.

6 Eligibility and registration

6.1 Inclusion criteria

Diagnosis of primary intracranial germ-cell tumour

- Except in specific situations as described in section 7.1, diagnosis should be pathologically verified and be confirmed by central review whenever possible. Central review will be done by:

*Prof. dr. J.M. Kros, neuropathologist,
Erasmus Medical Centre/location Centrum
Dr. Molewaterplein 40
3015 GD ROTTERDAM,
email: j.m.kros@erasmusmc.nl*

- Age \geq 18

6.2 Registration

After diagnosis and informed consent all adult patients with a primary CNS germ-cell tumour should be registered at the IKNL Trial bureau (Integraal Kankercentrum Nederland), c/o UMCU huispost F02-162 postbus 85500 3508 GA Utrecht. Tel: 088-755 6286, fax: 088-755 5462.

At least the following information should be registered for each patient:

- date of birth;
- sex;
- patient hospital registration number;
- treating physician; and
- date of registration.

7 Treatment

7.1 Diagnostic work-up

Complete assessment of the extent of disease using MR imaging of brain and spine, evaluation of tumour markers in serum and CSF and investigation of CSF for leptomeningeal dissemination is essential to determine optimal treatment. In addition a CT of thorax and abdomen and in men a testicular ultrasonography should be performed to exclude a non-CNS primary. Diagnostic investigations are summarized in the flow-chart (page 4) and the tables (p24,25). In addition endocrinologic screening is advised.

Imaging

Cranial MRI should be performed in all cases pre-operatively and within 48 hours following surgery if resection is performed (not required after biopsy only). Spinal MRI should ideally be performed before lumbar puncture and surgery and should include the full spine (C0–S3). Pre-contrast T1 sequences are mandatory, especially after surgery.

Tumour Markers

In patients suspected of harbouring an intracranial germ-cell tumour, assessment of tumour markers (AFP and HCG) in both serum and CSF must be performed. Since elevated markers in the context of a primary intracranial tumour are diagnostic of a germ-cell tumour, assessment of markers may obviate the need for biopsy as outlined in the flow-chart. Furthermore, elevated HCG may distinguish between germinoma and NGGCT.

Tumour markers are also used for response evaluation. Therefore, in patients with raised markers at diagnosis, tumour markers are to be repeated in serum if > 2 weeks have elapsed between diagnosis and the planned start of treatment and in CSF if > 4 weeks have elapsed.

CSF examination

GCTs may disseminate through the CSF and it is of utmost importance to stage patients completely before starting treatment. If possible, CSF should be sampled before neurosurgical intervention for pathologic examination and evaluation of tumour markers. If, however, lumbar puncture is not possible before surgery, CSF may be sampled pre-operatively but before biopsy.

Biopsy

Biopsy is mandatory in all patients except those with:

- a) typical MRI findings and elevated serum and/or CSF AFP (> 25 µg/l) (diagnosis NGGCT)
 - b) bifocal disease (pineal and suprasellar only) with normal AFP (diagnosis germinoma)
- Central pathology review is advised in all patients.

Systemic evaluation

Presentation of a systemic germ-cell tumour with an intracranial metastasis is exceedingly rare. Nevertheless, given the clinical consequences of concurrent systemic disease, CT evaluation of chest and abdomen and, in males, testis ultrasonography is advised.

7.2 Neurosurgery

Tumour biopsy

Biopsy can be performed either with neuronavigation guided techniques, stereotactic procedures as well via an endoscopic approach.

Treatment of hydrocephalus

In cases of hydrocephalus CSF shunting may be necessary. If technically possible, an endoscopic third ventriculostomy is preferable to placement of a ventriculoperitoneal shunt. An additional benefit of neuroendoscopy is the ability to simultaneously perform tumour biopsy. Collection of CSF (to assess tumour markers and leptomeningeal dissemination) is strongly recommended and easy to perform in a neuroendoscopic procedure or ventriculoperitoneal shunt placement. CSF must be collected before biopsy or surgery of the tumour.

Indications for extensive procedures may be

- 1) Patients who suffer acute obstructive visual deterioration from a suprasellar mass.
- 2) Proven mature teratomas (after a previous biopsy) with normal tumour markers. In these patients gross total resection is recommended since surgery is curative and no further interventions are required.
- 3) Patients with a single residual mass after chemoradiotherapy within the non germinoma group. The tumour recurrence rate is much higher and the outcome shows a poorer prognosis, when compared with patients who do not have a residue. Small residual masses within the germinoma group that have responded to radiotherapy should not be resected but a watch and wait strategy should be the policy (SIOP CNS GCT 96 trial).
- 4) Patients with localized disease who do not show any response to chemoradiotherapy.

7.3 Radiation therapy

7.3.1 Treatment planning

Immobilisation and treatment position

- Patients will be immobilised according to institutional practice.
- Patients receiving CSA RT can be treated either prone or supine.
- For the tumour bed and/or the ventricular irradiation, patients should preferably be treated in a supine position (accuracy reasons).

Imaging for treatment planning

Tumour definition

- Planning CT preferably with i.v.- contrast and (if possible) pre-radiotherapy MRI with contrast (T1 weighted) for delineation of gross tumour volume (GTV).
- If no pre-radiotherapy planning MRI is performed, the post-operative or post-chemotherapy MRI can be used and fused to the planning radiotherapy CT scan.
- Preoperative and pre-chemotherapy MRI scans need to be used and fused to the planning scan for focal irradiation.

Ventricular irradiation

- The postoperative/post-chemotherapy scans are to be used. A T2-weighted 3D-MRI is preferable for the delineation of the ventricles for irradiation of ventricular fields.

Target volumes (based on SIOP CNS GCT II protocol 2009)

Irradiation of the tumour bed (as boost or sole treatment)

- Gross Tumour Volume (GTV) includes both the initial anatomically involved part of the brain and any post-chemotherapy (or post-surgery) residue.
- Clinical target volume (CTV): GTV plus a 3D-margin; when originating either in the suprasellar or pineal region a 3D-margin of 5 mm will be added. In “atypical” primary sites where local infiltration of normal tissues could be suspected (e.g. basal ganglia or thalamus) a margin of 10 mm is recommended.
- Planning target volume (PTV): CTV plus a 3D margin according to institutionally measured/defined accuracy is added (mostly this is in the range of 5 mm).

Whole ventricles plus tumour bed (VFI)

- GTV: the lateral ventricles, 3rd ventricle and 4th ventricle together with the tumour bed defined at the time of RT delivery (=post-operative/post-chemotherapy imaging).
- CTV: GTV plus a 3D-margin of 5 mm.
- PTV: CTV plus a 3D margin according to institutionally measured/defined accuracy is added (mostly this is in the range of 5 mm).

Craniospinal axis (CSI)

- CTV: the whole brain as well as the spinal cord the end of thecal sac.
- Width of the Spinal Volume: the entire subarachnoid space including the extensions along the nerve roots as far as the intervertebral foramina. The spinal CTV should extend laterally to cover the intervertebral foramina.
- PTV: An additional margin, generally 1.0 cm on either side should be added.
 - Whole Brain Volume:
The whole brain CTV should extend anteriorly to include the entire frontal lobe and cribriform plate region. In order to include the cribriform fossa within the CTV, and allowing an additional appropriate margin for PTV, the edge of the field (i.e. the geometric edge of the shielding block) would in many cases include the lenses. The geometric edge of the shield on the film should extend at least 0.5 cm inferiorly below the cribriform plate and at least 1 cm elsewhere below the base of the skull (paying particular attention to the margin around the inferior aspect of the temporal lobes). The margin between the shielding and the anterior border of the upper cervical vertebrae should be 0.5 cm. The lower border of the cranial fields should form a precise match with the upper border of the spinal field.
 - Cervical Spinal Volume:
As much as possible of the cervical spinal volume is included in the lateral cranial fields with the junction between the cranial and spinal fields kept as inferior as possible. This is advised for avoidance of as much thyroid tissue irradiation as possible, by shielding this within the "cranio-cervical" volume.
 - Dorso-Lumbar Spine Volume:
The inferior limit of the spinal CTV must be determined by imaging the lower limit of the thecal sac on a spinal MR and will usually extend inferiorly to at least the lower border of the second sacral vertebra.

Metastasis boost

- Where possible the initial extent of disease- or at treatment planning will be considered as CTV; in spinal deposits, the safety margin in cranio-caudal direction should be one vertebral body.

Organs at risk (OAR)

The following OAR to be outlined: lenses, optic chiasm, pituitary, cochlea, optic nerves, and for CSI thyroid, ovaries and testes - depending on the age of the patient.

Energy

- For irradiation of the craniospinal axis energies in the range of 4-6 MV should be used. to avoid under-dosage to the lateral meninges due to dose built up effect.
- For spinal irradiation electrons of suitable energy can be used as an alternative.

7.3.2 Pure germinoma

Indication

AFP not increased in serum or CSF. β -HCG value plays no role for decision making of radiotherapy.

Timing

RT should start as soon as possible but no later than 4-6 weeks from diagnosis.

The largest prescribed volume should be treated first.

No metastases (M0) and PR after chemotherapy

Dose and fractionation

Volume	Total dose	Fraction dose	No. Fractions
VFI and tumour bed (ventricles and tumour + 5mm)	24	1.6	15
Boost to tumour bed (Tumour + 5 mm)	16	1.6	10
Tumour bed total	40	1.6	25

To note: 1) Germinoma occurring in the basal ganglia require a larger additional CTV margin in addition to the ventricles (10 mm); 2) Bifocal tumours (i.e. tumours both in the pineal and suprasellar region) should also be treated by VFI; 3) Incompletely staged germinoma should also receive CSI; 4) if component of teratoma, incompletely or not resected: increase tumourbed dose boost up to 54.4 Gy.

Spinal metastases (M1) or incompletely staged

Indication: diagnosis based on imaging and/or positive liquor or incomplete staging

Dose and fractionation

Volume	Total dose	Fraction dose	No. Fractions
CSI	24	1.6	15
Boost to tumour bed and metastases (Tumour + 5 mm)	16	1.6	10
Tumour bed total	40	1.6	25

7.3.3 Non-germinomatous germ-cell tumours

Indication

- teratoma, embryonal carcinoma, choriocarcinoma, yolk sac tumours and mixed germ cell tumours

Timing

- *After chemotherapy:* RT will start after haematological recovery of the patients, usually within 3-4 weeks following the last cycle of chemotherapy.
- *Without chemotherapy:* RT should start as soon as possible but no later than 4-6 weeks from diagnosis.
- The largest prescribed volume should be treated first.

No metastases (M0)

Dose and fractionation

Volume	Total dose	Fraction dose	No. Fractions
Tumour bed (pre-chemo/surgery tumour + 5mm)	54	1.8	30

Spinal metastases (M1)

Indication: diagnosis based on imaging and/or positive liquor

Dose and fractionation

Volume	Total dose	Fraction dose	No. Fractions
CSI	30	1.5	20
Boost to tumour bed and intracranial metastases (Pre-chemo/pre-surgery tumour + 5 mm)	24	1.6	15
Spinal metastases	20.8	1.6	13
Total dose to tumour and intracranial metastases	54	1.5 / 1.6	35
Total dose to spinal metastases	50.8	1.6	33

If more than 2/3 of the spine is involved with macroscopic disease the total dose will be limited to 45 Gy (additional boost dose: 15 Gy in 10 daily fractions of 1.5 Gy).

7.3.4 Toxicity during CSI

Thrombocytopenia

CSI will be interrupted if a platelet count of $<25 \times 10^9/L$ is observed. In this case platelet transfusions will be given. CSA RT will restart when the platelet count is $>40 \times 10^9/L$.

Neutropenia

If a neutrophil count of $<0.5 \times 10^9/L$ occurs, then the craniospinal component of radiotherapy maybe interrupted and the tumour boost will continue to be given.

Anaemia

The haemoglobin level should be maintained at a minimum level of 6.2 mmol/L during RT by transfusion if necessary.

Radiation oesophagitis

Symptomatic management e.g. with analgesics and antifungal medication.

Routine laboratory studies

during RT: 1-2 weekly complete blood count

(If the patient is receiving steroid medication: blood glucose 1x weekly)

7.4 Chemotherapy, schedules and management

7.4.1 Germinoma

In view of the excellent results of radiotherapy only, chemotherapy is not indicated for adults with intracranial germinoma, irrespective of stage.

7.4.2 Non-germinomatous germ cell tumours (PEI also known as VIP)

In view of the poor prognosis of these patients, all patients will be treated with 4 courses of cisplatin, etoposide and ifosfamide (PEI). In males, the possibility of sperm cryopreservation should be discussed prior to the initiation of chemotherapy. In females, gonadal protection may be considered, and should be based on local or national recommended practice.

After 4 courses, evaluation will take place. All patients will be irradiated after chemotherapy.

Figure 1. Schematic representation of chemotherapy in the treatment

4xPEI		
Evaluation		
CR	PR/SD	PD
	resection when resectable	palliative radiotherapy
radiotherapy	radiotherapy	

PEI chemotherapy

Each course of PEI consists of:

- Cisplatin 20 mg/m²/day days 1, 2, 3, 4, 5
- Etoposide 100 mg/m²/day days 1, 2, 3
- Ifosfamide 1500 mg/m²/day days 1, 2, 3, 4, 5

Courses should be given at 21 day intervals, subject to count recovery.

Details of chemotherapy administration

It is advised to insert a central venous catheter according to local practice for the delivery of this chemotherapy.

- *Cisplatin* (20 mg/m², days 1, 2, 3, 4, 5) should be given over one hour, and must be accompanied by an adequate diuresis. In the absence of diabetes insipidus (DI), this should be achieved with a forced diuresis according to local practice (with mannitol or furosemide).
- *Etoposide* (100 mg/m², days 1, 2, 3) should be diluted to <0.3mg/ml in 0.9% saline (NaCl) and given over one to four hours (according to institutional practice), prior to cisplatin and ifosfamide.
- *Ifosfamide* (1500 mg/m², days 1, 2, 3, 4, 5) is given after cisplatin, over 3 hours by continuous infusion with hydration and mesna (uromexitan), to prevent bladder toxicity.

Other nephrotoxic drugs, including aminoglycoside antibiotics, should be used with caution with ifosfamide and cisplatin.

Supportive care during chemotherapy

Mesna

Mesna should be given, according to local protocol, but at a dose of at least 100-120% of the daily ifosfamide dose, starting prior to cisplatin infusion. It is recommended that this is given as a continuous infusion (alongside or added to hydration fluid). In the rare event of haemorrhagic cystitis, mesna or hydration should be increased and diuretics added, according to institutional practice.

Hydration fluid

Hydration fluid should commence at least one hour before start chemotherapy and continue throughout the infusions of cisplatin and ifosfamide, at a total rate (including chemotherapy) of at least 125ml/m²/hour (3l/m²/day) and continue until 24 hours from the end of the cisplatin infusion. 2.5% glucose 0.45% saline should be used with potassium, magnesium and calcium additives. The following concentrations are recommended:

- 20 mmol KCl per litre
- 10 mmol MgSO₄ per litre
- 0.6 mmol Ca Gluconate per litre

Depending on the volumes used for drugs, the total fluid volume in addition to the hydration fluid is likely to be significant. Consideration should be given to capping this at 3.5l/m²/day or 4l/m²/day.

Note: For patients with diabetes insipidus, consultation with an endocrinologist is advised in order to prevent severe electrolyte disturbances. Particular attention must be paid to urine output and plasma electrolytes in these patients, especially in those without perception of thirst.

Anti-emetic treatment

Recommended anti-emetic treatment includes a 5HT₃-antagonist, metoclopramide and aprepitant. Administration of steroids (e.g. dexamethasone) during chemotherapy should be avoided if at all possible, and only used for anti-emesis if other therapies fail.

Prophylactic antibiotics

The prophylactic use of cotrimoxazole (sulfamethoxazole/trimethoprim) is optional and should be based on local practice, as no case of pneumocystis jirovecii pneumonitis has been reported in the SIOP CNS GCT 96 series. Prophylactic antibiotic/antifungal decontamination may be used if it is the normal practice in the treating hospital. The choice of antibiotics used during episodes of febrile neutropenia should be based on local guidelines.

Hematopoietic growth factors

Hematopoietic growth factors are not indicated after the first course. In case of neutropenic fever or delay of next course of chemotherapy due to neutropenia, administration of G-CSF is indicated (rather than decreasing dose).

7.4.3 Toxicity, dose modification and treatment delay

Hematological toxicity

- Courses of chemotherapy should be delayed until haematological recovery from the previous course has taken place, defined by neutrophils of at least 0.5 x 10⁹/l and platelets 100 x 10⁹/l.
- In case of febrile neutropenia: consider adding granulocyte-colony stimulating factor in following courses.
- In case of macroscopic hematuria (>10 RBC/HPF): elevate mesna dose to 2400 mg/m²/day; ensure adequate hyperhydration with normal serum electrolytes and sufficient urine output. Consider intravesical treatment with NaCl 0.9%. In acute severe cases: consult an urologist immediately for bladder instillation therapy.

At start of course:

- neutrophil granulocytes ≥0.5 x 10⁹/l and
- trombocytes ≥100 x 10⁹/l

Otherwise course should be delayed for one week. If after one week blood counts have recovered, employ 100% dose in case of neutropenia without thrombopenia and add granulocyte-colony stimulating factor. If thrombopenia was the cause for delay, or if granulocyte-colony stimulating factor was already administered after the previous course, a 25% dose reduction of etoposide should be performed. When hematological toxicity requires delay of > 2 weeks despite dose reduction of etoposide, the coordinating team of the LWNO should be consulted.

Ototoxicity (lowest grade of best performing ear)

Grade	Subjective hearing loss	Audiometry	Treatment adjustment
0	no change	loss < 40 db	None
1	no change	loss \geq 40 db at 8000 Hz	None
2	tinnitus	loss \geq 40 db at 4000 Hz	switch cisplatin to carboplatin AUC 4
3	function interference; hearing aid needed	loss \geq 40 db at 2000 Hz	omit any platinum
4	deafness not correctable	loss \geq 40 db at 1000 Hz	omit any platinum

AUC = area under the curve

Nephrotoxicity (cisplatin)

- Calculated GFR <60 ml /min/1.73 m²
- Serum creat >1.5 x ULN

Delay course with one week. After one week delay GFR should be measured by 24 hours urine collection. If repeat GFR still < 60 ml /min/1.73 m², *switch cisplatin to carboplatin AUC 6.*

Neurotoxicity (Ifosfamide)

Cerebral adverse events can occur and are characterised by diminished consciousness, deliriousness, anxiety and hallucinations. Recovery can be a matter of days to weeks. Beneficial effects were seen by administration of methylene blue 6 x 50 mg/day i.v. and of thiamine 6 x 100 mg in 100 ml NaCl 0.9% in 10 minutes i.v. In subsequent courses, prophylactic methyleneblue 6 x 50 mg IV daily should be considered. In case of recurrence, substitution with cyclofosfamide 800 mg/m² on day 1 only may be considered.

7.4.4 Investigations before each course of chemotherapy

- Clinical examination including neurological assessment and WHO-ECOG performance status
- Weight
- Full blood count
- Blood biochemistry: electrolytes, urea, creatinine, ALT/AST, Alkaline phosphatase, bilirubin, albumin, magnesium, calcium, phosphate
- Serum markers (AFP and total HCG)
- Creatinine clearance calculated by Cockcroft-Gault formula
- Pure tone audiometry (if indicated)

7.4.5 Tumour evaluation during chemotherapy

Serum markers

Before each course of chemotherapy, serum markers AFP and HCG will be determined. The calculated half life of AFP is 5–7 days, and for HCG around 50 hours. If markers rise during chemotherapy and if the elevation cannot be accounted for by this half-life, radiotherapy must be considered if imaging studies confirm progression. It is recognized that markers may increase in the first one to two weeks after the first course of PEI ('surge') despite chemosensitivity, and calculations should take that into account.

Imaging

After the 4th course of PEI, MRI scanning of the brain will be performed. In case of irresectable progressive disease, 2nd line chemotherapy may be considered after consultation of a specialized centre. Otherwise immediate radiotherapy is advised. In case of suspicion of early progression based on rising markers or neurological symptoms, imaging may be done earlier.

7.5 Follow-up

See Chapter 8, Tables of evaluations.

MR imaging, as well as clinical and neurologic examination and serum tumour markers should be done 6-12 weeks after the end of treatment. Thereafter if possible every 4 months in the first year, every 6 months in the second and third year and yearly thereafter until year 5. The MRI should be made of the brain in all patients. Additionally, in patients with abnormal spinal MRI at diagnosis spinal MRI should be repeated at the end of treatment and thereafter on clinical indication and at least with every other cranial MRI. In NGGCT with elevated markers at diagnosis markers should be evaluated two-monthly after treatment in the first year, 3-monthly in the second year, 6-monthly in the third year and yearly thereafter until 5 years.

8 Table of evaluations

Table 1. Required evaluations in germinoma patients treated with radiotherapy only

Observation	Preoperatively	After resection	Prior to RT	During RT	At the end of RT	After treatment
Physical and neurological exam	X	X	X	Weekly	X	X ^c
Weight			X	Weekly	X	
WHO performance			X	Weekly	X	
MRI brain	X	X ^a			X	X ^b
MRI spine	X				X ^c	X ^c
CSF cytology	X					
CSF tumor markers	X				X	
Serum tumor markers	X	X			X	X ^b
CBC	X		X	Weekly if CSI	X	

a) Only after resection, not necessary after biopsy: within 48h

b) Every 4 months 1st year, every 6 months second year, yearly thereafter until 5 years

c) Only repeat if positive at outset, at least with alternate brain MRIs and if symptomatic

Table 2. Required observations in non-germinoma patients treated with chemotherapy and radiotherapy

Observation	Preoperatively	Postoperatively	Prior to each PEI	Prior to RT	During RT	At the end of RT (6-12 wks after)	Follow-up
Physical and neurological exam	X	X	X	X	Weekly	X	X ^c
Height (prior to first PEI)			X				
Weight			X	X		X	
Performance status			X	X	Weekly	X	
NCI-CTC toxicity			X	X	Weekly	X	
MRI brain	X	X ^a		X		X	X ^b
MRI spine	X			X ^c		X ^c	X ^c
CSF cytology	X						
CSF tumor markers	X			X ^d		X	
Serum tumor markers	X		X	X		X	X ^e
CBC			X	X	Weekly	X	
Blood chemistry ^f			X	X			
Audiometry	X		X ^g				

a) Only after resection, not necessary after biopsy: within 48h

b) Every 4 months 1st year, every 6 months second year, yearly thereafter until 5 years

c) Only repeat if positive at outset, at least with alternate brain MRIs and if symptomatic

d) Consider if positive at outset and clinically indicated

e) 2-monthly in 1st year, 3-monthly second year, 6-monthly 3rd year, thereafter yearly until 5 years

f) Sodium, potassium, calcium, magnesium, creatinine, Cockcroft creatinine clearance, blood urea nitrogen, bilirubine, ASAT, ALAT, GGT, LDH. Additionally endocrinologic evaluation if clinically required.

g) Prior to first chemotherapy, thereafter on indication only.

9 References

- (1) Kaatsch P, Rickert CH, Kuhl J, Schuz J, Michaelis J. Population-based epidemiologic data on brain tumors in German children. *Cancer* 2001 Dec 15;92(12):3155-64.
- (2) Kamoshima Y, Sawamura Y. Update on current standard treatments in central nervous system germ cell tumors. *Curr Opin Neurol* 2010 Dec;23(6):571-5.
- (3) Sloetjes KG, van den Bergh JP, Wesseling P, Otten BJ, Pieters GF, Hermus AR. [Clinical presentation, treatment, and follow-up of 32 patients with a primary intracranial germinoma, registered during the previous 15 years in the Dutch Pathological-Anatomical National Automated Archive (PALGA)]. *Ned Tijdschr Geneesk* 2000 Nov 18;144(47):2264-8.
- (4) Matsutani M, Sano K, Takakura K, Fujimaki T, Nakamura O, Funata N, et al. Primary intracranial germ cell tumors: a clinical analysis of 153 histologically verified cases. *J Neurosurg* 1997 Mar;86(3):446-55.
- (5) Blakeley JO, Grossman SA. Management of pineal region tumors. *Curr Treat Options Oncol* 2006 Nov;7(6):505-16.
- (6) Matsutani M. Combined chemotherapy and radiation therapy for CNS germ cell tumors--the Japanese experience. *J Neurooncol* 2001 Sep;54(3):311-6.
- (7) Aoyama H, Shirato H, Ikeda J, Fujieda K, Miyasaka K, Sawamura Y. Induction chemotherapy followed by low-dose involved-field radiotherapy for intracranial germ cell tumors. *J Clin Oncol* 2002 Feb 1;20(3):857-65.
- (8) Germ cell tumours. In: Louis DN, Oghaki H, Wiestler OD, Cavenee WK, editors. *WHO Classification of Tumours of the Central Nervous System*. Lyon, France: IARC; 2007. p. 198-204.
- (9) Germ cell tumours. In: Berger MS, Prados MD, editors. *Textbook of Neuro-Oncology*. Philadelphia: Elsevier Inc; 2005. p. 310-20.
- (10) Ogino H, Shibamoto Y, Takanaka T, Suzuki K, Ishihara S, Yamada T, et al. CNS germinoma with elevated serum human chorionic gonadotropin level: clinical characteristics and treatment outcome. *Int J Radiat Oncol Biol Phys* 2005 Jul 1;62(3):803-8.
- (11) Inamura T, Nishio S, Ikezaki K, Fukui M. Human chorionic gonadotrophin in CSF, not serum, predicts outcome in germinoma. *J Neurol Neurosurg Psychiatry* 1999 May;66(5):654-7.
- (12) Sawamura Y, de TN, Ishii N, Abe H. Management of primary intracranial germinomas: diagnostic surgery or radical resection? *J Neurosurg* 1997 Aug;87(2):262-6.
- (13) Finlay J, da Silva NS, Lavey R, Bouffet E, Kellie SJ, Shaw E, et al. The management of patients with primary central nervous system (CNS) germinoma: current controversies requiring resolution. *Pediatr Blood Cancer* 2008 Aug;51(2):313-6.
- (14) Luther N, Edgar MA, Dunkel IJ, Souweidane MM. Correlation of endoscopic biopsy with tumor marker status in primary intracranial germ cell tumors. *J Neurooncol* 2006 Aug;79(1):45-50.
- (15) Souweidane MM, Krieger MD, Weiner HL, Finlay JL. Surgical management of primary central nervous system germ cell tumors: proceedings from the Second International Symposium on Central Nervous System Germ Cell Tumors. *J Neurosurg Pediatr* 2010 Aug;6(2):125-30.
- (16) Wong KT, Koh KB, Lee SH, Chee CP. Intracranial germinoma metastasizing via a ventriculo-peritoneal shunt. *Singapore Med J* 1996 Aug;37(4):441-2.
- (17) Haw C, Steinbok P. Ventriculoscope tract recurrence after endoscopic biopsy of pineal germinoma. *Pediatr Neurosurg* 2001 Apr;34(4):215-7.
- (18) Cho J, Choi JU, Kim DS, Suh CO. Low-dose craniospinal irradiation as a definitive treatment for intracranial germinoma. *Radiother Oncol* 2009 Apr;91(1):75-9.

- (19) Nguyen QN, Chang EL, Allen PK, Maor MH, Ater JL, Mahajan A, et al. Focal and craniospinal irradiation for patients with intracranial germinoma and patterns of failure. *Cancer* 2006 Nov 1;107(9):2228-36.
- (20) Schoenfeld GO, Amdur RJ, Schmalfuss IM, Morris CG, Keole SR, Mendenhall WM, et al. Low-dose prophylactic craniospinal radiotherapy for intracranial germinoma. *Int J Radiat Oncol Biol Phys* 2006 Jun 1;65(2):481-5.
- (21) Bamberg M, Kortmann RD, Calaminus G, Becker G, Meisner C, Harms D, et al. Radiation therapy for intracranial germinoma: results of the German cooperative prospective trials MAKEI 83/86/89. *J Clin Oncol* 1999 Aug;17(8):2585-92.
- (22) Maity A, Shu HK, Janss A, Belasco JB, Rorke L, Phillips PC, et al. Craniospinal radiation in the treatment of biopsy-proven intracranial germinomas: twenty-five years' experience in a single center. *Int J Radiat Oncol Biol Phys* 2004 Mar 15;58(4):1165-70.
- (23) Eom KY, Kim IH, Park CI, Kim HJ, Kim JH, Kim K, et al. Upfront chemotherapy and involved-field radiotherapy results in more relapses than extended radiotherapy for intracranial germinomas: modification in radiotherapy volume might be needed. *Int J Radiat Oncol Biol Phys* 2008 Jul 1;71(3):667-71.
- (24) Rogers SJ, Mosleh-Shirazi MA, Saran FH. Radiotherapy of localised intracranial germinoma: time to sever historical ties? *Lancet Oncol* 2005 Jul;6(7):509-19.
- (25) Haas-Kogan DA, Missett BT, Wara WM, Donaldson SS, Lamborn KR, Prados MD, et al. Radiation therapy for intracranial germ cell tumors. *Int J Radiat Oncol Biol Phys* 2003 Jun 1;56(2):511-8.
- (26) Jensen AW, Laack NN, Buckner JC, Schomberg PJ, Wetmore CJ, Brown PD. Long-term follow-up of dose-adapted and reduced-field radiotherapy with or without chemotherapy for central nervous system germinoma. *Int J Radiat Oncol Biol Phys* 2010 Aug 1;77(5):1449-56.
- (27) Merchant TE, Sherwood SH, Mulhern RK, Rose SR, Thompson SJ, Sanford RA, et al. CNS germinoma: disease control and long-term functional outcome for 12 children treated with craniospinal irradiation. *Int J Radiat Oncol Biol Phys* 2000 Mar 15;46(5):1171-6.
- (28) Ogawa K, Shikama N, Toita T, Nakamura K, Uno T, Onishi H, et al. Long-term results of radiotherapy for intracranial germinoma: a multi-institutional retrospective review of 126 patients. *Int J Radiat Oncol Biol Phys* 2004 Mar 1;58(3):705-13.
- (29) Tseng CK, Tsang NM, Wei KC, Jaing TH, Pai PC, Chang TC. Radiotherapy to primary CNS germinoma: how large an irradiated volume is justified for tumor control? *J Neurooncol* 2003 May;62(3):343-8.
- (30) Borg M. Germ cell tumours of the central nervous system in children-controversies in radiotherapy. *Med Pediatr Oncol* 2003 Jun;40(6):367-74.
- (31) Wolden SL, Wara WM, Larson DA, Prados MD, Edwards MS, Sneed PK. Radiation therapy for primary intracranial germ-cell tumors. *Int J Radiat Oncol Biol Phys* 1995 Jul 15;32(4):943-9.
- (32) Foote M, Millar BA, Sahgal A, Menard C, Payne D, Mason W, et al. Clinical outcomes of adult patients with primary intracranial germinomas treated with low-dose craniospinal radiotherapy and local boost. *J Neurooncol* 2010 Dec;100(3):459-63.
- (33) Huh SJ, Kim IH, Ha SW, Park CI. Radiotherapy of germinomas involving the basal ganglia and thalamus. *Radiother Oncol* 1992 Nov;25(3):213-5.
- (34) Sonoda Y, Kumabe T, Sugiyama S, Kanamori M, Yamashita Y, Saito R, et al. Germ cell tumors in the basal ganglia: problems of early diagnosis and treatment. *J Neurosurg Pediatr* 2008 Aug;2(2):118-24.
- (35) Lafay-Cousin L, Millar BA, Mabbott D, Spiegler B, Drake J, Bartels U, et al. Limited-field radiation for bifocal germinoma. *Int J Radiat Oncol Biol Phys* 2006 Jun 1;65(2):486-92.
- (36) Nasta A, Krieger M, Gonzalez I, Villablanca J, Jubran R, Anderson C, et al. Treatment of primary CNS germinomas: The Children's Hospital Los Angeles experience, 1985–2005. *2005 Nov 18; 2005 p. 520.*

- (37) Weksberg DC, Shibamoto Y, Paulino AC. Bifocal Intracranial Germinoma: A Retrospective Analysis of Treatment Outcomes in 20 Patients and Review of the Literature. *Int J Radiat Oncol Biol Phys* 2011 Jun 11.
- (38) Jennings MT, Gelman R, Hochberg F. Intracranial germ-cell tumors: natural history and pathogenesis. *J Neurosurg* 1985 Aug;63(2):155-67.
- (39) Balmaceda C, Heller G, Rosenblum M, Diez B, Villablanca JG, Kellie S, et al. Chemotherapy without irradiation--a novel approach for newly diagnosed CNS germ cell tumors: results of an international cooperative trial. The First International Central Nervous System Germ Cell Tumor Study. *J Clin Oncol* 1996 Nov;14(11):2908-15.
- (40) Baranzelli MC, Patte C, Bouffet E, Portas M, Mechinaud-Lacroix F, Sariban E, et al. An attempt to treat pediatric intracranial alphaFP and betaHCG secreting germ cell tumors with chemotherapy alone. SFOP experience with 18 cases. *Societe Francaise d'Oncologie Pediatrique. J Neurooncol* 1998 May;37(3):229-39.
- (41) Buckner JC, Peethambaram PP, Smithson WA, Groover RV, Schomberg PJ, Kimmel DW, et al. Phase II trial of primary chemotherapy followed by reduced-dose radiation for CNS germ cell tumors. *J Clin Oncol* 1999 Mar;17(3):933-40.
- (42) Robertson PL, DaRosso RC, Allen JC. Improved prognosis of intracranial non-germinoma germ cell tumors with multimodality therapy. *J Neurooncol* 1997 Mar;32(1):71-80.
- (43) Calaminus G, Andreussi L, Garre ML, Kortmann RD, Schober R, Gobel U. Secreting germ cell tumors of the central nervous system (CNS). First results of the cooperative German/Italian pilot study (CNS sGCT). *Klin Padiatr* 1997 Jul;209(4):222-7.
- (44) Schmoll HJ, Souchon R, Krege S, Albers P, Beyer J, Kollmannsberger C, et al. European consensus on diagnosis and treatment of germ cell cancer: a report of the European Germ Cell Cancer Consensus Group (EGCCCG). *Ann Oncol* 2004 Sep;15(9):1377-99.
- (45) Modak S, Gardner S, Dunkel IJ, Balmaceda C, Rosenblum MK, Miller DC, et al. Thiotepa-based high-dose chemotherapy with autologous stem-cell rescue in patients with recurrent or progressive CNS germ cell tumors. *J Clin Oncol* 2004 May 15;22(10):1934-43.
- (46) Ogawa K, Toita T, Nakamura K, Uno T, Onishi H, Itami J, et al. Treatment and prognosis of patients with intracranial nongerminomatous malignant germ cell tumors: a multiinstitutional retrospective analysis of 41 patients. *Cancer* 2003 Jul 15;98(2):369-76.
- (47) Kamoshima Y, Sawamura Y, Ikeda J, Shirato H, Aoyama H. Late recurrence and salvage therapy of CNS germinomas. *J Neurooncol* 2008 Nov;90(2):205-11.
- (48) Kim A, Ji L, Balmaceda C, Diez B, Kellie SJ, Dunkel IJ, et al. The prognostic value of tumor markers in newly diagnosed patients with primary central nervous system germ cell tumors. *Pediatr Blood Cancer* 2008 Dec;51(6):768-73.

Appendix A: Checklist protocollaire behandeling met PEI bij intracerebrale non-germinomen

I Behandelschema

Etoposide (E)	100 mg/m ²	dag 1–3	i.v.
Ifosfamide (I)	1500 mg/m ²	dag 1–5	i.v.
Cisplatine (P)	20 mg/m ²	dag 1–5	i.v.
Mesna	volgens lokaal protocol, 1500-1800 mg/m ²	dag 1–5	i.v.
In totaal 4 kuren à 3 weken, klinisch, 5 dagen kuur, 6 ^e dag naar huis			

II Voorbereiding en toediening

Bij aanvang van de kuur mag er geen sprake zijn van dehydratie: indien hierop vermoeden bestaat patiënt eerst rehydreren.

Etoposide (E)	100 mg/m ²	in 1000 ml NaCl 0,9%	in 1–4 uur
Cisplatine (P)	20 mg/m ²	in 1000 ml NaCl 0,9%	in 1 uur
Ifosfamide (I)	1500 mg/m ²	in 1000 ml NaCl 0,9 %	in 1 uur

III Supportive care

Voorafgaand aan aanvang therapie *sperma en eicellen preservatiemethoden* overwegen. Afspraken maken rondom contraceptie.

Ondersteunend ter voorkoming hypokaliëmie en hypomagnesiëmie bij hyperhydratie

Na cisplatin infuus gedurende volgende 16 uur elke 8 uur 20 mmol KCl, 10 mmol MgSO₄ en 0.6 mmol Cagluconaat in 1000 NaCl 0,9%.

Weegprotocol

Ter voorkoming van nefrotoxiciteit bij de cisplatinum wordt hyperhydratie toegepast. Om te voorkomen dat patiënten onder of overvuld raken wordt het weegprotocol gehanteerd. Voor start van de hyperhydratie wordt de patiënt gewogen - dit is het uitgangsgewicht, tijdens de kuur wordt 2xdaags de patiënt gewogen. Indien het gewicht 2 kg boven het uitgangsgewicht is, wordt 20 mg furosemide i.v. gegeven. Bij patiënten met hart- of nieraandoeningen, lymfoedeem of ascites gelden strengere regels.

Anti-emetica suggestie

Dag 1: aprepitant 120 mg 1xdaags p.o. Dag 2-3: aprepitant 80 mg 1xdaags p.o.

Dag 1-5: ondansetron 8 mg 1xdaags i.v. en zo nodig 1xdaags i.v. extra.

Thuismedicatie: mee geven

Metoclopramide 10-20 mg 3–4xdaags zo nodig (max 60 mg dd) en ondansetron 8 mg 2xdaags zo nodig.

Bij falen bovenstaande anti-emetica schema:

Dexamethason	dag 1	dag 2–3	dag 4–5	Stop
	10 mg i.v.	2 dd 6 mg	2 dd 3 mg	

Nefrotoxische geneesmiddelen

Zo mogelijk vermijden: diuretica, NSAIDs, calcineurineremmers (tacrolimus, ciclosporine), aminoglycosiden (bijv. gentamycine, tobramycine), amfotericine.

Profylactische antibiotica

Overwegen: co-trimoxazole 480 mg 1xdaags (PJP profylaxe), ciproxine 500 mg 1xdaags dag 5–15 (atypische verwekkers profylaxe)

IV Dosisaanpassingen en uitstel behandeling

Hematologische toxiciteit

- Bij neutropene koorts: neulasta starten na volgende kuur;
- Bij hematurie (>10 RBC/HPF): ophogen mesna dosis tot 2400 mg/m²/dag en controleren of er een adequate hyperhydratie is gegeven met afdoende urineproductie; blaasspoelingen kunnen worden overwogen. Bij acute ernstige blaasbloedingen onmiddellijk uroloog in consult vragen ter beoordeling van blaasinstillaties aangezien deze bloedingen levensgevaarlijk kunnen worden.

Bij aanvang kuur:

- neutrofiële granulocyten $\geq 0.5 \times 10^9/l$ en
- trombocyten $\geq 100 \times 10^9/l$

anders uitstel kuur met 1 week. Als na 1 week het beenmerg hersteld is, wordt de volgende kuur 100% gedoseerd in geval van neutropenie zonder thrombopenie, en wordt granulocyt-Kolonie stimulerende factor (G-CSF, i.e. Neulasta[®] 6 mg d. 6 SC) toegediend. Als de kuur werd uitgesteld vanwege thrombopenie, of als G-CSF al toegediend was bij de vorige kuur, wordt 25% dosisreductie van etoposide toegepast. Bij >2 weken uitstel ondanks eerder ingestelde dosisreductie etoposide, overleg met medisch oncologen uit team LWNO.

Ototoxiciteit (laagste graad van beste oor)

Graad	Subjectief gehoorverlies	Audiometrie	Dosisaanpassing
0	geen verschil	verlies <40 db	Geen
1	geen verschil	verlies ≥ 40 db op 8000 Hz	Geen
2	tinnitus	verlies ≥ 40 db op 4000 Hz	i.p.v. cisplatine carboplatin AUC 4
3	functie interfererend; nood aan gehoorstoestel	verlies ≥ 40 db op 2000 Hz	geen platinum
4	doofheid niet te corrigeren	verlies ≥ 40 db op 1000 Hz	geen platinum

AUC = area under the curve

Nierfunctiestoornissen

- Berekend GFR <60 ml /min/1.73 m²
- Serum creat >1.5 x ULN

Uitstel kuur met 1 week. Vervolgens meten GFR door 24 uren urine-bepaling. Indien GFR <60 ml /min/1.73 m², vervang cisplatine in carboplatine AUC 6.

Ifosfamide geïnduceerde neurotoxiciteit

Cerebrale bijwerkingen kunnen optreden en karakteriseren zich door verminderd bewustzijn, verwardheid, angst en hallucinaties. Herstel kan dagen tot weken duren. Gunstige effecten zijn waargenomen bij toediening van methyleenblauw 6x50 mg/dag i.v. en van thiamine 6x100 mg in 100 cc NaCl 0.9% in 10 minuten i.v. Na eenmaal opgetreden neurotoxiciteit dient bij vervolgguren profylactisch methyleenblauw 6 dd 50 mg IV te worden toegediend.

Endocrinopathie

In geval van diabetes insipidus wordt een consult bij een endocrinoloog aanbevolen om ernstige electrolytstoornissen te voorkomen. Bijzondere aandacht is vereist voor vochtbalans en plasma electrolyten in deze patiënten, met name bij patiënten zonder dorstgevoel.

V Routine bepalingen tijdens behandeling

- 1) Voor aanvang behandeling (op indicatie): audiometrie, ECG, gemeten GFR (24-uurs urine).
- 2) Voor iedere kuur: gewicht, tensie, pols, L.O. met neurologische evaluatie, Hb, leuco+diff, thrombo, Na, K, Mg, calcium, fosfaat, albumine, ureum, creatinine, berekende GFR bepaling, bilirubine, ASAT, ALAT, AF, γ GT, LDH, AFP, β HCG.
- 3) Tijdens chemotherapie dagelijks urinesediment ter bepaling van microscopische hematurie en kreatinine in bloed bepalen.
- 4) Einde behandeling: Hb, leuco+diff, thrombo, Na, K, Mg, calcium, fosfaat, albumine, ureum, creatinine, bilirubine, ASAT, ALAT, AF, γ GT, LDH, AFP, β HCG, audiometrie, gemeten GFR bepaling (24-uurs urine).

VI Mogelijke bijwerkingen

Misselijkheid, braken, moeheid, stomatitis, alopecia, hemorragische cystitis, leverfunctiestoornissen, beenmergtoxiciteit, infertiliteit, nefrotoxiciteit, neurotoxiciteit, cardiotoxiciteit, ototoxiciteit, allergische reacties, encephalopathie, secundaire tumoren.

VII Evaluatie tijdens behandeling

- 1) MRI cerebrum +/- contrast na 4 kuren. Overweeg MRI CWK-LWK.
- 2) AFP, β HCG en cytologie in CSF (bij afwijkingen voor aanvang therapie) na 4 kuren.
- 3) Overweeg chirurgie bij resectabel restletsel na 4 kuren.
- 4) Radiotherapie, *eventueel gevolgd door re-operatie*.

Literatuur

Pelgrims J, De Vos F, Van den Brande J, Schrijvers D, Prové A, Vermorken JB. Methylene blue in the treatment and prevention of ifosfamide-induced encephalopathy: report of 12 cases and a review of the literature. Br J Cancer. 2000 Jan;82(2):291-4.

Behandelschema gebaseerd op SIOP CNS GCT II protocol.

Appendix B: ZUBROD-ECOG-WHO Performance Status

Grade	
0	Normal activity
1	Symptoms, but nearly ambulatory
2	Some bed time, but to be in bed less than 50% of normal daytime
3	Needs to be in bed more than 50% of normal daytime
4	Unable to get out of bed

Appendix C: RTOG neurologic function status

Grade	
0	No neurologic symptoms; fully active at home/work without assistance
1	Minor neurologic symptoms; fully active at home/work without assistance
2	Moderate neurologic symptoms; fully active at home/work but requires assistance
3	Moderate neurologic symptoms; less than fully active at home/work and requires assistance
4	Severe neurologic symptoms; totally inactive requiring complete assistance at home or institution - unable to work

Appendix D: MR imaging – minimal requirements

MRI scanner - minimally 1.0T (magnetic field strength)

MRI brain

- 1) unenhanced T1W;T2W; axial; FLAIR axial or coronal.
 - slice thickness no more than 5 mm
 - DWI (diffusion) – optional
- 2) after gadolinium: T1 W axial; coronal, sagittal; slice thickness no more than 5 mm

MRI spine

- 1) unenhanced T1W en T2W sagittal; slice thickness no more than 4 mm
- 2) after gadolinium: T1W sagittal; slice thickness no more than 4 mm
transversal slices at the level(s) of abnormalities